

# Split hand foot malformation: Presentation of a rare case and description of a novel technique in management of split hand Study design: Case report

Sudhir Kumar Mahapatra<sup>1</sup>

## Abstract

Split hand foot malformation syndrome (SHFM) is a rare condition. The management of split hand depends on the severity of first web space narrowing, degree of split, presence of incomplete or extra ray and syndactyly. For the type II B Manske and Halikis hand trans position of second metacarpal along with first web space widening and split excision has been recommended. However this needs microsurgical expertise. In the present paper we report a case of isolated SHFM and a novel technique of corrective osteotomy of the second metacarpal instead of transposition. This is a much simpler technique with similar results.

**Keywords:** Split hand foot malformation, Split hand reconstruction, Metacarpal osteotomy

## Introduction

Ectrodactyly, split hand, cleft hand is a central deficiency i.e. "V"-shaped cleft in the centre of hand/foot and absence of central fingers/toes without any deficiency of proximal nerves, vessels, tendons, muscles or bones. The upper limb deformity is also known as lobster claw hand. In atypical cleft hand the symbrachydactyly proceeds in the ulnar direction from thumb [1,2,3]. The pathophysiology of cleft hand is thought to be a result of a wedge-shaped defect of the apical ectoderm of the limb bud (AER: Apical Ectodermal Ridge) appearing around 41 days of gestation [4]. The incidence of cleft hand is 1 in 10,000-90,000 births depending on the type of reports. The inheritance is mostly autosomal dominant with varied phenotype. Some of the syndromes with split hand as a component are listed in table 1 [1,2].

The clinical presentation varies widely from an inconsequential split to absent fingers and thumb and the management will depend upon each case. Manske and Halikis have described the most widely used classification (table 2).

The broad components that need attention are narrowing of first web space, the split between thumb/index and the ring finger, the incomplete/extra ray, syndactyly [1,5]. In this case report we present a case of split hand foot malformation (SHFM) and a novel technique in management of split hand.

## Case report

A 3 years boy, only child of nonconsanguinous parents presented with


deformities of hands and feet since birth. In hand both side had similar median cleft between second and fourth rays. The first web space had mild narrowing. Both index fingers had radial deviation at middle phalanx with right side more than left. There was no syndactyly (fig.1). X-ray showed normal metacarpals, absent phalanges of third finger and radial deformities of index finger middle phalanges (fig.2).

In right foot the great toe was short and arising from the mid portion of foot. The interphalangeal joint was stiff and laterally deviated. Other toes were short stiff and medially deviated. In the left foot all toes were medially deviated for varying degrees with symbrachydactyly of third and fourth toes and cleft in second web space (fig. 3). In x-ray right foot had short metatarsal, left foot had medially deviated first and second metatarsals, and horizontal phalanx in third toe (fig. 4). For the parents cosmetic deformity of hand and inability to use normal shoes was the main concern.

As the hand deformity was primary concern, correction of both hands was planned first. Through dorsal approach a flap raised over the second metacarpal, and the third metacarpal was excised. The second metacarpal was then osteotomised at the base and fixed in ulnar deviation to close the intermetacarpal gap. Distal end of second and fourth metacarpals were then approximated with 4-0 monofilamentous nonabsorbable sutures. Flaps were then closed with the extra skin being transferred for the widening of the first web space (fig. 5). Postoperative below elbow slab and bulky dressing were applied. The k-wire was removed at 4 weeks and patient was allowed for hand movement. At the latest follow up the finger and hand movements were full with the patient and parents being happy about the cosmetic appearance.

## Discussion

Split hand foot malformation (SHFM) is a type of birth defect that consists of missing digits (fingers and/or toes), a deep cleft down the center of the hand or foot, and fusion of remaining digits and is either



<sup>1</sup>Department of Orthopaedics, SCB Medical College, Cuttack, Odisha, India

Address of Correspondence  
Dr. Sudhir Kumar Mahapatra,  
SCB Medical College, Cuttack, Odisha, India  
E-mail: dr.sudhir.2k@gmail.com

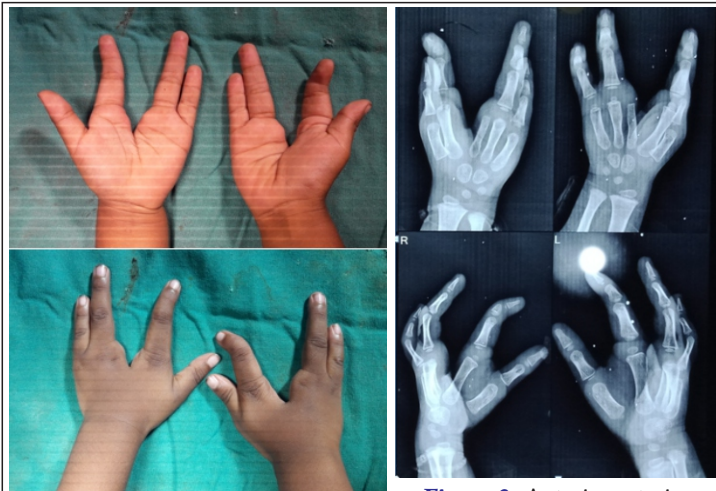

Figure 1: Clinical picture of split hand

Figure 2: Anteroposterior radiographs of the hands

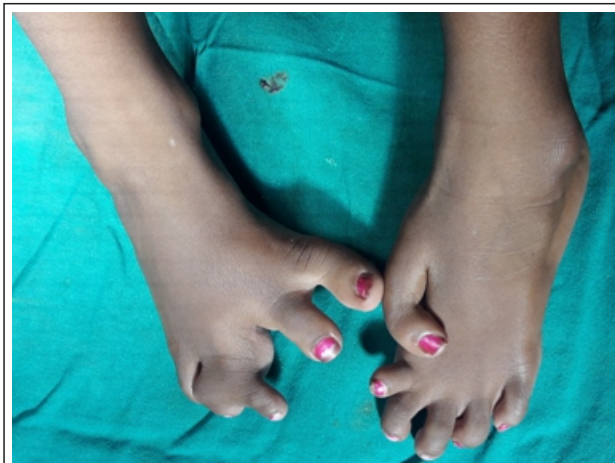

Figure 3: Clinical pictures of the feet

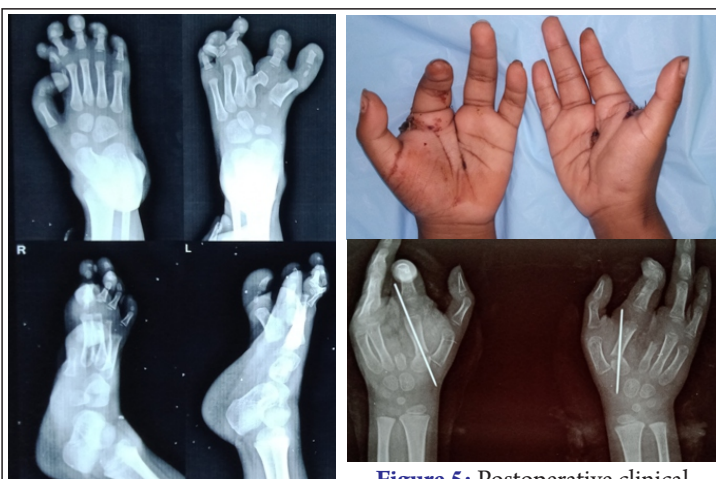

Figure 4: Anteroposterior and lateral radiographs of both feet

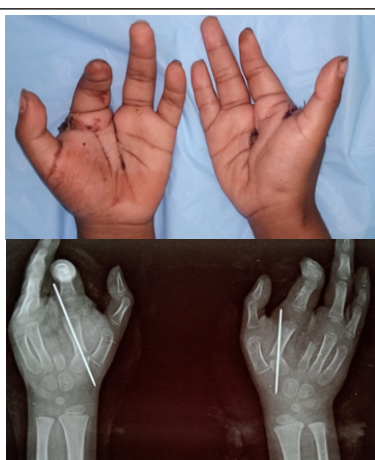

Figure 5: Postoperative clinical pictures and anteroposterior radiographs of both hands

Table 1: Syndromes associated with split hand

Split hand foot malformation (SHFM)
Ectrodactyly ectodemral dysplasia cleft (EEC)
Cornelia de Lange syndrome
Acrorenal syndrome
Focal dermal hypoplasia
Ectrodactyly and cleft palate syndrome
Ectrodactyly/mandibulofacial dysostosis
Ectrodactyly and macular dystrophy

duplication of digit or phalanx thus type IIB as per Manske and Halikis classification [5].

For the type IIB split hand Manske and Halikis had proposed 1st web space reconstruction and transposition of the 2nd metacarpal. To reduce the future possibility of recurrence of the cleft widening fixation of the 2nd to 4th metacarpal and reconstruction of intermetacarpal ligaments by suturing of flaps from flexor tendon sheath [1,5]. However the transposition of the 2nd metacarpal to the base of may stretch the compromised vascularity of the 2nd finger. Thus it needs microsurgical training and facilities to avoid such complication which may not be available at all centres. In this patient we did a redirection osteotomy of the 2nd metacarpal. This helps in reducing the cleft gap without a transposition. A interosseous suturing of the 2nd and 4th metacarpal with 3-0 polypropylene. At 3 weeks the k-wires and skin sutures were removed and finger movements were started. As the periosteum was not disturbed, union was relatively faster and mobilization could be started early. At 6 months the osteotomy has united well with full range of finger movement.

**Conclusion**

Split hand foot syndrome is a rare deformity. Sporadic nonsyndromic involvement is even rarer. For type II B cleft hand metacarpal osteotomy is a simpler procedure as compared to metacarpal transposition with similar end results.

isolated or it may be part of a syndrome [1,2,3,6]. There are six different forms of isolated SHFM (table 3). These are due to mutation of various transcription factors resulting in formation of abnormal protein formation. Of the various types of SHFM type 1,2,5,6 are very rare and have been reported only in few cases. Type 4 is the most common type accounting for the >90% syndromic and 10-16% of non-syndromic cases [4,7,8]. The present case was a sporadic case without any family history.

The congenital anomalies were restricted to hands and feet. There were no craniofacial, auditory abnormalities, orofacial clefting or longitudinal limb deformities. The clefting in hands were typical cleft. Thumb was with 1st web space narrowing without any

Type	Description	Management
I	Normal 1 <sup>st</sup> web	Reconstruction of the transverse metacarpal ligament
IIA	Mild narrowing	
IIB	Severely narrowed	Transposition of the index metacarpal with reconstruction of the thumb webspace
III	Syndactyly thumb & index ray	
IV	Merged web with suppressed index	Mobility and/or position of the thumb of ulnar digit to promote pinch and
V	Absent web, only ulnar element remains	Creating a radial digit

**Table 3: Types of Split hand foot malformation (SHFM)**

Type	Gene	Function of gene	Chromosome and inheritance	Mutation	Other clinical features
1	SEM1	Removal of damaged proteins	7: AD/AR	Polymorphic	EEC, MR, deafness
2	FRMD7	Nerve cell function	X : XR	Duplication	Symbrachydactuly
3	CYP2C8	Lipid metabolism and synthesis	10: AR	Duplication	Triphalangeal and duplicated thumb
4	TP63	Early ectodermal growth	3:AR	Missense	EEC, VATER, MR, dental, hearing, lacrimal malformation
5	HOXD4	Homeobox gene	2:AR	Deletion	MR, cleft lip, ectodermal and craniofacial anomalies
6	WNT10B	Encodes signalling protein	12:AD	Nonsense	Tibial hypoplasia

## References

- Kay SP, McCombe D. Central hand deficiencies. In Green DP, Hotchkiss, Robert N, Pederson W et al. 2005. Green's Operative Hand Surgery (5th ed.). Philadelphia: Elsevier/ Churchill Livingstone. pp. 1404–15.
- Ectrodactyly. Wikipedia. <https://en.wikipedia.org/wiki/Ectrodactyly>
- U.S. Department of Health & Human Services. National Institutes of Health. NCATS. <https://rarediseases.info.nih.gov/diseases/6319/split-hand-foot-malformation>
- Pascal HGD, Hansvan B, Han GB. Pathogenesis of split-hand/split-foot malformation. Human Molecular Genetics. 2003;12(1):R51–R60
- Manske PR, Halikis MN. Surgical classification of central deficiency according to the thumb web. The Journal of Hand Surgery. 1995; 20(4): 687–97
- Katarincic JA. Cleft Hand. American Society for Surgery of the Hand. 2003;3(2):108-16
- Sowińska-Seidler A, Socha M, Jamsheer A. Split-hand/foot malformation - molecular cause and implications in genetic counseling. J Appl Genet. 2014;55(1):105-15
- U.S. National Library of Medicine. Genetic Home Reference. [ghr.nlm.gov/gene](http://ghr.nlm.gov/gene)

Conflict of Interest: NIL  
Source of Support: NIL

### How to Cite this Article

Mahapatra S K. | Split hand foot malformation: Presentation of a rare case and description of a novel technique in management of split hand Study design: Case report. | Odisha Journal of Orthopaedics and Trauma | January 2020; 01: 28-30.