

# Fracture of C1 vertebra managed with unilateral trans articular screw fixation- Report of two cases

Hemanta Kumar Bamidi<sup>1</sup>, Satya Ranjan Patra<sup>1</sup>, Siddhartha Shankar Mohanty<sup>1</sup>,  
Kishore Chandra Das<sup>1</sup>

## Abstract

Fracture of C1 vertebrae nearly accounts for 2-13% of cervical spine injury. The fracture may be stable or unstable. If both anterior and posterior arch of atlas is fractured then it is considered an unstable type and needs surgical intervention. Various fixation methods have been described by researchers. We describe two cases of unstable C1 fractures managed with trans-articular screw fixation by minimal invasive technique. Trans-articular screw fixation is a less invasive and safe method for unstable C1 fractures.

**Keywords:** C1 vertebrae [atlas], Jefferson fracture, Dens fracture, Trans-articular screw fixation

## Introduction

Fractures of the first cervical or Atlas vertebrae (C1) account for 2-13 % of injuries to the cervical spine [1]. The entity is more common at younger age among males (57-69 %), but in the elderly, a female predominance is observed (52 %) [2]. The fracture of C1 was first described by Astley Cooper in 1822, and later elaborately described by Jefferson in 1920. Most commonly C1 fracture is caused under axial loading force and hyper-extension of neck because the lateral mass of this vertebrae is wedge shaped. Axial loading creates a hoop stress and bone failure occurs at the weakest points that are just anterior & posterior to the lateral mass [3]. Type 2 atlas fractures, Type 2 dens fracture, mid substance transverse ligament tear and presence of atlantooccipital instability, ADI more than 5mm—need surgical interventions [3].

The Atlas vertebra articulates with the head. It lacks vertebral body, ring shaped and composed of two lateral masses interconnected by an anterior arch and a posterior arch. Each lateral mass articulates with an occipital condyle of the skull and below with the superior articular process of Axis. The posterior surface of the anterior arch has an articular facet for the dens which is held in a position by a strong transverse ligament. And the anterior aspect is secured by the anterior atlantoaxial ligament, posteriorly by the posterior atlantoaxial ligament.

Atlas fractures can involve various and multiple structures and follow a number of patterns. Burst, lateral mass & laminar fractures are all recognized injuries. Single fractures involving the ring are highly unlikely and a ring disruption typically accompanies any fractures [4]. Atlanto occipital dislocations are another fracture pattern with

Atlas involvement. The Jefferson burst fracture is another variety which includes fracture of both anterior and posterior arch, rarely presents with no neurological deficits as the displacement of the fragment occurs away from the spinal canal. Sometimes involves axis also which is categorised by Anderson and D'Alonzo's classification (table 2).


## Case Reports

### Case-1

A 32-year male complaining of neck pain following trauma admitted to emergency ward. Physical examination revealed noneurological abnormalities. Plain radiographs of the cervical spine showed fracture of the C1 vertebra (Fig. 1A,1B) and it was confirmed by computed tomography (Fig.1C). Initially neck was stabilized by a Philadelphia collar. Surgical stabilization was planned with trans-articular screw fixation. Patient was placed in prone position after administering general anesthesia, (Fig.1D) under all aseptic conditions one incision was made over the posterior neck approaching the C2 facets (Fig.1E). The other incision was made further distally near the C7 spinous process for introducing the screw in correct trajectory. Entry point of the screw was made over the C2 facet using a specialized instrument set supplied by the manufacturer (Synthes) (Fig.1F). The direction of the screw is such as to engage the facets of C1 and C2 vertebrae. It is critical to avoid injury to the vertebral arteries or violating the spinal canal and spinal cord. The procedure was performed under fluoroscopy guidance. Post-operative radiographs were taken for evaluation (Fig.1G,1H,1I).

### Case-2

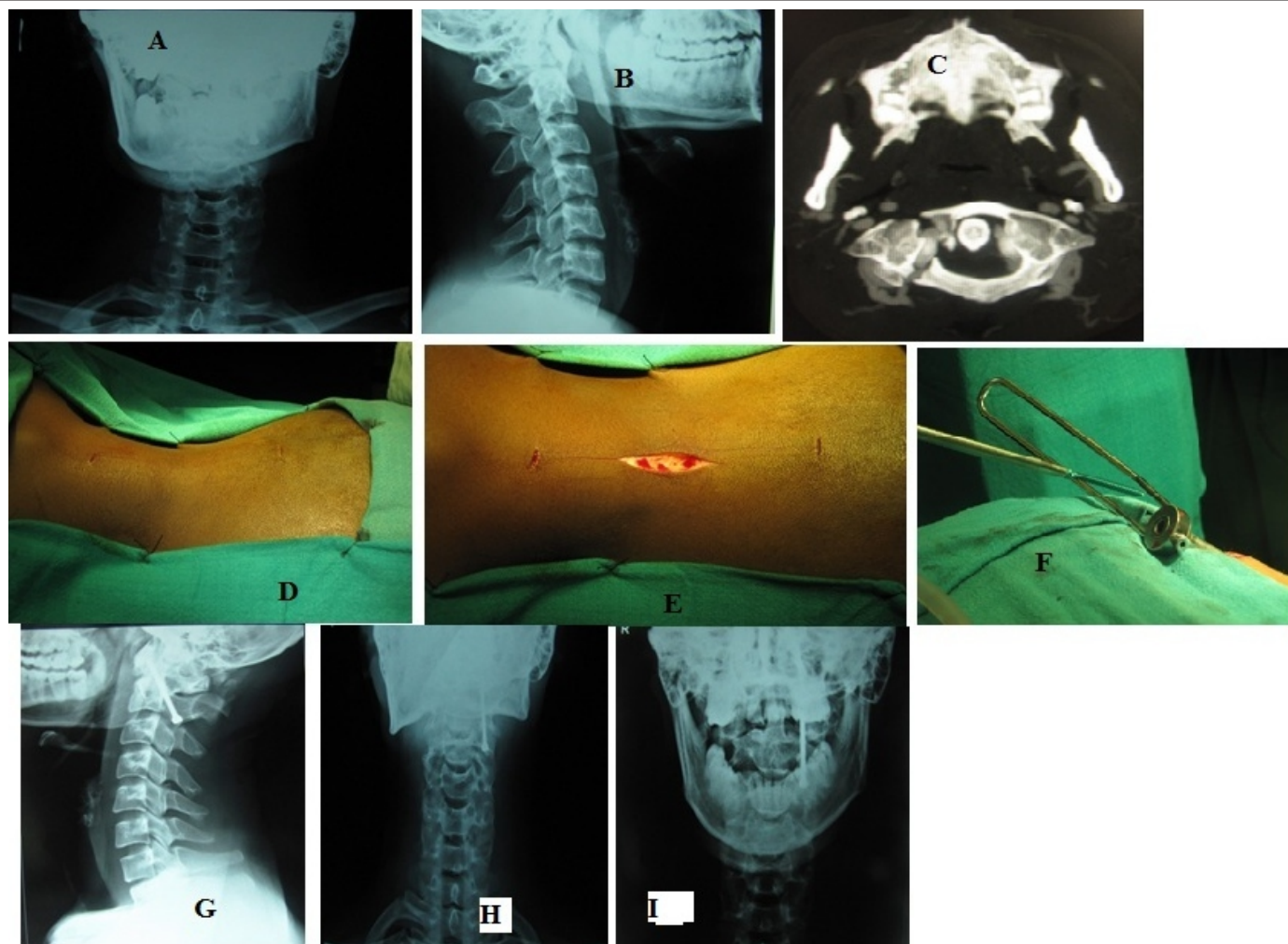
A 40 years female admitted in our hospital with complain of neck pain following trauma without any neurological deficit. On routine radiographs and CT scan fracture of both anterior and posterior arch was confirmed (Fig 2A, 2B). Unilateral trans-articular screw fixation was done by the same minimally invasive methods (Fig. 2C,2D,2E). Further evaluation was done post-operatively using radiographs and



<sup>1</sup>Department of Orthopaedics, Hi-Tech Medical College & Hospital, Bhubaneswar, Odisha India.

#### Address of Correspondence

Dr. Satya Ranjan Patra,  
Hi-Tech Medical College & Hospital,  
Bhubaneswar, Odisha India  
E-mail: drsatyarp@gmail.com



**Figure 1:** [A] X-ray of cervical spine (Antero-posterior View) showing fracture of C1 vertebrae. [B] X-ray of cervical spine (lateral view) showing fracture of C1 vertebrae, [C] Computed tomography of cervical spine confirming the fracture of both anterior & posterior arch of C1 vertebrae, [D] Draping & Painting of Surgical site putting patient in prone position, [E] Surgical Incision, [F] Showing insertion of screw intra-operatively, [G] X-ray of cervical spine (Antero-posterior view) showing fracture fixation with screw, [H] X-ray of cervical spine (Lateral view) showing fracture fixation with screw, [I] X-ray of cervical spine (odontoid view) showing fracture fixation with screw

Tables 1:
Landells and Van Petegham modified Jefferson's classification
Type 1-Isolated anterior/posterior arch fracture
Type 2-Includes anterior and posterior part of the ring [Jefferson #]
Type 3-Includes lateral mass with/without a fracture of the ring

Table 2:
Anderson and D'Alonzo's classification
Type-1-Fracture of the dens superior to cruciform ligament
Type-2-Fracture of the base of the dens below the cruciform ligament
Type-3-Fracture involves base of the dens and lateral mass of the axis

neurological examinations at regular intervals (Fig. 2F).

Both patients were immobilized with Philadelphia collars post-operatively for almost 12 weeks to allow fusion between C1 and C2. Gentle static cervical exercises were continued to maintain muscle tone. Mobilization of the neck was started after 3 months under supervision.

Patients were regularly followed up to two years. There were no significant symptoms except occasional neck ache and slight restriction of rotation of head. Regular evaluation was done by assessing the sensory as well as motor systems by clinical methods. There were no neurological problems or any significant difficulty in activities of daily living.

**Discussion**

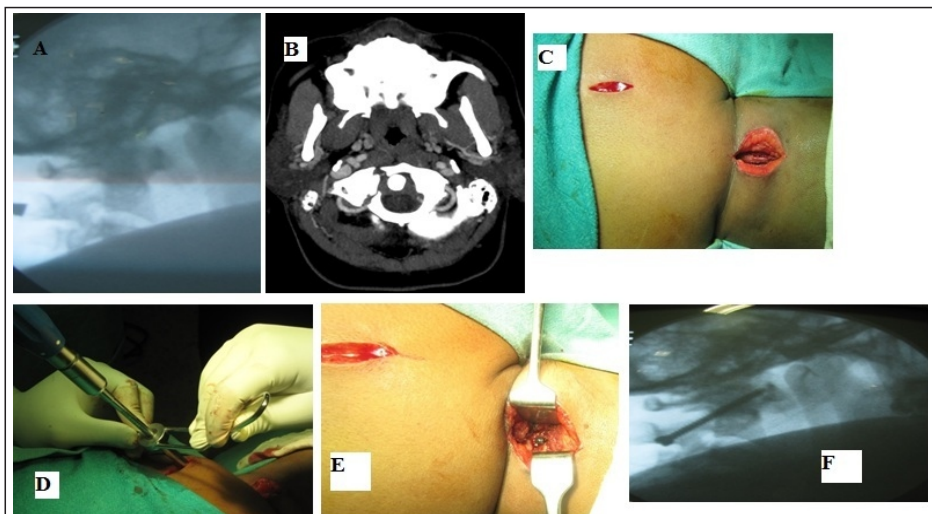
Neck pain is the most common presentation of Jefferson fractures. Neurological injuries are uncommon since the large diameter of the spinal canal is further widened by centrifugal displacement of the fragments. Standard radiographs of occipito-cervical junction are often inadequate. Hence, a high index of suspicion must be

maintained in these patients who sustained axial compression injuries. The integrity of the transverse ligament determines the stability of this type of fractures. Transverse ligament injuries are classified into intra substance tears (type I) or bony avulsion fractures of the ligament from C1 lateral mass (type II). Type II injuries show a promising 74% healing rate with conservative management, while type I injuries exhibit poor healing rates that warrant surgical intervention. An atlanto-dens interval of 3mm or cumulative lateral mass displacement. 8.1mm on open mouth odontoid view radiograph simply rupture of the transverse ligament and hence fracture instability [8]. Isolated atlas fractures are very difficult to diagnose in plain radiograph, it needs a computed tomography scan if only bony structures involved or else magnetic resonance imaging if ligaments are involved. The Atlanto-dens interval [ADI] can also be used to rule out ligamentous instability, normally it is less than 3mm and more

distance indicates ligamentous injury.

Various treatment protocols have been described for these fractures. Isolated atlas fractures-without displacement (type 1 and type 3) can be managed with rigid cervical collars. Isolated atlas fracture with displacement (type 1 and type 3) may be managed with halo vest (external immobilizer) for 6 to 8 weeks if ring is intact and up to 10 to 12 weeks if ring is disrupted. Type 2 atlas fractures, Type 2 dens fracture, mid substance transverse ligament tear and presence of atlanto-occipital instability with ADI more than 5mm usually need surgical interventions [3]. Odontoid fracture in combination with C1 fracture treated by anterior odontoid and trans-articular (C1-C2) screw fixation [5]. Trans-articular atlanto-axial screw fixation for treatment of C1-C2 instability [6]. C1-C2 injury managed with trans-articular screw fixation [7]. Both the cases presented here are unstable type II atlas fracture involving both anterior and posterior arches. Such fractures are observed to

be prone to non-union (33.3%) across both operative and non-operative management [9]. Unstable Jefferson fractures are normally treated with fusion. Unfortunately, fusion causes loss of range of motion nearly 52 degree in flexion extension plane & 38.9 degree in rotation [10]. The technique employed here was direct fixation of C1 with a unilateral trans-articular screw fixation through posterior approach. This approach provides good exposure of the entry point, stable fixation, which enables the transverse ligament to heal and achieve stable fibrous union and also preserve range of motion. Both our patients are doing well following surgery after more than two years follow up, without too much restriction in motion or any neurological deficit. Trans-articular screw fixation appears to be a reliable method to manage unstable C1 fractures with good clinical outcome.



**Figure 2:** [A] X-ray of cervical spine (lateral view) showing fracture of C1 vertebrae, [B] Computed tomography of cervical spine confirming the fracture of both anterior & posterior arch of C1 vertebrae, [C] Draping & Painting of Surgical site putting patient in prone position with incision, [D] Showing insertion of screw intra-operatively, [E] Showing implant in-situ intra-operatively, [F] X-ray of cervical spine (Lateral view) showing fracture fixation with screw.

## References

1. Marcon RM et al, Cristante AF, Teixeira WJ, NarasakiDK, Oliveira RP, Fractures of cervical spine. Clinics (Sao Paulo). 2013;68(11):1455-61
2. Matthissen C, Yohan R. Epidemiology of atlas fractures-a national registry based cohort study of 1537 cases. Spine J. 2015;15(11):2332-7. doi:10.1016/j.spinee.2015.06.052.
3. Keith D. Williams, Campbell Operative Orthopaedics, 13th Editions, page no 1785.
4. Hadley MN, Curtis DA, Garrett M, Consiglieri G Acute traumatic atlas fractures: management and long term outcome. Neurosurgery. 1988;23(1):31-5.
5. Josten C Jarvers JS, Glasmacher S, Spiegl UJ, Arch Orthop Trauma Surg. 2018 Nov;138(11):1525-1531. doi: 10.1007/s00402-018-3013-y. Epub 2018 Jul 28.
6. Toussaint P, Desenclos C, Peltier J, Le Gars D. Neurochirurgie. 2003 Nov;49(5):519-26. French.
7. Wright N M Laurysen C. J Neurosurg. 1998 Apr;88(4):634-40. Review.
8. Aravind kumar, international journal of spine surgery, vol.13, No.4, 2019, pp.345-349
9. Llu M, Charles YP, Blondel B, et al. C1 fracture: analysis of consolidation and complications rates in a prospective multicenter series. Orthop Traumatol Surg Res. 2018;104(7):1049-1054.
10. Panjabi M, Dvorak J, Crisco J III, Oda T, Hilibrand A, Grob D. Flexion extension and lateral bending of upper cervical spine in response to alar ligament transections. J Spinal Disord. 1991;4(2):157-167.



Conflict of Interest: NIL  
Source of Support: NIL

#### How to Cite this Article

Bamidi H K, Patra S R, Mohanty S S, Das K C. | Fracture of C1 vertebra managed with unilateraltrans articular screw fixation- report of two cases. | Odisha Journal of Orthopaedics & Trauma | January 2020; 41: 34-37.