

Comparison of the Outcomes of Intra-articular Distal Femur Fracture Managed With Distal Femoral Nail and Locking Compression Plate: A Prospective Study

Manoranjan Mallick¹, Gopal Chandra Sethi¹, Abinash Ray¹, Debi Prasad Nanda¹

Abstract

Background: The treatment of intra articular distal femur fracture still remains a debatable issue. The need for anatomical reduction and maintenance of the joint congruity while giving the patient a painless mobile knee is quite challenging. There is little Indian literature evidence comparing the functional outcome after treatment with distal femoral nail and locking compression plate in these group pf fractures. We decide to clear this gap in knowledge by this current study.

Material and methods: This was a prospective study Of 20 patients with closed intra-articular distal femoral fracture treated either with distal femoral nail or locking compression plate. It was carried out in the Department of Orthopaedics, SCB Medical College, and Cuttack during the period of August 2017 to November 2019 and functional results are analysed with 100 point scores by Neer et al i.e. Neer's criteria.

Result: Average healing time was better in the case of nailing (15.2 weeks) than plating (18 weeks) which was assessed both clinically and radiologically. The average knee flexion range of motion was better in case of nailing (112°) than plating (93°). With the Neer's score, Excellent result was obtained in 90% cases in nailing comparing to only 30% with plating where as fair and poor result was obtained in 10% cases in nailing comparing to 70% with plating.

Conclusion: In the present study, retrograde nailing was found to be a better fixation system for both extra as well as intra-articular fractures (type C1 & type C2) of distal femur with better outcome in terms of range of movements, early mobilization, union and less operative time and blood loss.

Keywords: Intra-Articular Fractures, Bone Plates, Range of Motion, Articular

Introduction

The incidence of distal femoral fractures is approximately 37 per 1,00,000 person per year¹. Distal femoral fractures are defined as "Fractures up to 15 cm from distal femoral articular surface It accounts for 6-7% of the fractures of the femur". Mainly two different mechanisms of injury cause fractures of the distal femur. In the older osteoporotic population, it occurs predominately after low-energy trauma like falls and sprain and have complications associated with comorbidities². In younger patients, high-energy trauma causes complex injury with comminuted and open fracture pattern. Many patients also suffer polytrauma, ligament or meniscal tears, dissected cartilage fragments and patellar fractures. Most of these fractures require to be treated operatively to achieve optimal patient outcomes. Internal fixation has the advantage of early ambulation and early knee range of motion exercises which reduces chances of knee stiffness^{3,4}. Currently, with the evolution of implants and fixation, the modes of treatment have been focused on Locked


plating, Intramedullary nailing or angled blade plates.

A retrograde intramedullary nail aligns the femoral shaft with condyles, reducing the tendency for varus movement at the fracture site and has the advantages like preservation of fracture haematoma, less blood loss, minimal soft tissue dissection, less operative time and reduced rate of infection. Distal femoral locking plates have shown promising results in both intra and extra-articular fractures of the distal femur, especially in osteoporotic bones⁵. The locked compression plate is a single beam construct where the strength of its fixation is equal to the sum of all screw-bone interfaces rather than a single screws axial stiffness or pullout resistance as seen in unlocked plates.

In this prospective study, we evaluated and compared the clinical, radiological and functional outcome of the intraarticular type of distal femur fracture stabilization using retrograde nailing and locking compression plate.

Materials & Methods

The study was carried out in the Department of Orthopaedics, SCB Medical College, Cuttack during the period of August 2017 to November 2019. It comprised of the management of intra-articular distal femoral fracture and their results treated by either retrograde intramedullary nailing or with locking compression plate. A total of 20 patients with distal femur fracture were treated, out of which 10 underwent retrograde nailing and the rest were treated with



¹Department of Orthopaedics, SCB Medical College

Address of Correspondence
Dr. Debi Prasad Nanda,
Department of Orthopaedics, SCB Medical College
E-mail: drdebiortho@gmail.com

© 2021 Odisha Journal of Orthopaedics & Trauma | Available on www.ojotonline.com | DOI: 10.13107/ojot.2021.v42i01.018

This is an Open Access article distributed under the terms of the Creative Commons Attribution Non-Commercial License (<http://creativecommons.org/licenses/by-nc/3.0>) which permits unrestricted non-commercial use, distribution, and reproduction in any medium, provided the original work is properly cited.

locking compression plating.

Inclusion Criteria:

1. Age group 18 to 70 years of either sex .
2. AO type C1, and type C2 distal femur fracture or fracture with intercondylar extension.
3. All cases of distal femur fracture medically fit for surgery.
4. Patients with compound grade-1 injuries
5. Patients who give informed consent and willing for follow up

Exclusion Criteria

1. AO type A, type B and type C3 .
2. Patients less than 18 years of age & more than 70yr.
3. Patients unfit for surgery.
4. Associated comorbid conditions history of suffering from Myocardial Infarction (MI) less than 1 year, psychiatric illness, head injury.
5. Uncontrolled Diabetes Mellitus (DM), Hypertension, Patients with the clinically detectable focus of active infection.
6. Pathological fracture.
7. Fracture involving patellar fracture and neurovascular injury

Soon after admission, a detailed history was taken, relating to the age, sex and occupation, mode of injury, past and associated medical illness and then they were immediately kept in a proximal tibial skeletal traction over a Bohler Braun splint till surgery. This helped to prevent movements over the fracture site and to reduce pain and spasm of surrounding muscles. Anteroposterior and lateral radiographs of the distal femur including the knee were studied to classify the fractures. A routine X-ray of the pelvis done to rule out any hip injury. Group 1 (10 patients) were treated by distal femoral locking plate while Group 2 (10 patients) were treated by distal femoral nailing.

After obtaining informed consent, the patient was kept for surgery. Epidural anaesthesia was given and the patient was positioned as per the desired surgery. An intravenous antibiotic (cefuroxime) was given on the table just before starting surgery.

In Group 1 the patient was kept in a supine position & the standard lateral approach to the distal femur was carried out. The articular fragments were temporarily secured with pointed reduction forceps and K wires. The condyles were secured with 6.5 mm cancellous screws. Using anatomic landmarks and C – arm imaging, the plate was mounted on the reconstructed condyle beneath the vastus lateralis muscle.

In Group 2 patients a bolster was kept underneath the knee so that the knee was in 50 to 60-degree flexion. The condyles were reduced with K-wires as joystick guided under fluoroscopy & it was maintained with the help of a pointed reduction clamp. Two cancellous cannulated screws were inserted in both the condyles from lateral to medial direction , one anterior and other posterior in such a way that the nail can be passed between those screws. A 5-cm incision was made starting from the lower pole of the patella and just medial to the patellar tendon. The intercondylar notch was palpated and the guide pin was placed just above and medial to the femoral attachment of the posterior cruciate ligament and confirmed

by means of anterior-posterior and lateral fluoroscopy. The medullary canal was reamed and the nail of appropriate size was inserted. All the cases were statically locked with at least 2 distal locking screws and the nail was buried 3mm deep to the distal articular cartilage of the femur.

The Patients were followed up every month till 6 months thereafter 12 & 18 months and passive knee movement was allowed gradually as per the patient comfort level.

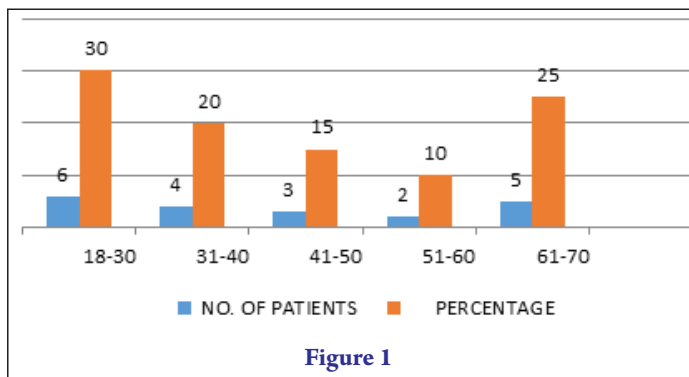
Results

In this present study 20 cases of intraarticular distal femur fracture were treated at our institute. All cases were treated either with distal femoral nailing or by locking compression plating. The age of the patients varied from 18 to 70 years with mean age(45.95±15.39) . The age distribution showed a bimodal peak with one peak in the younger age group due to high energy trauma and another peak in the older age group with osteoporotic bone due to trivial trauma. Out of 20 patients, 12 (60%) were male and 8 (40%) were female. The male to female ratio was 3:2.

The most common cause was RTA with 11(55%) patients. 13 (65%) patients had fractures of the right side while 7 (35%) patients had fractures of the left side. The fractures were classified according to the AO classification. Type-A , Type-B and Type-C3 fractures were not included in our study. Out of 20 cases, 13 (65%) cases were type C1 and 7 (35%) cases were type C2.

Average healing time was better in case nailing (15.2 weeks) than plating (18 weeks) which was assessed both clinically and radiologically for every month for 6 months and thereafter at 9 months and 12 months. All fractures are united by 5 months except 2 cases which took 7 months.

The knee flexion range of motion was examined at each visit and the final assessment was done at 6 months. In this study, the average knee flexion range of motion was better in the case of nailing (112°) than



Duration	Nailing		Plating	
	No. of cases	Percentage	No. of cases	Percentage
10-15 weeks	6	60	1	10
15-19 weeks	3	30	4	60
>20 weeks	1	10	5	30
Total	10	100	10	100

(p-value=0.042) (p-value significant at <0.05)

Knee flexion range in degrees	Nailing		Plating	
	No. of cases	Percentage	No. of cases	Percentage
<90	0	0	4	40
90-110	5	50	5	50
>110	5	50	1	10
Total	10	100	10	100

(p-value=0.0356.) (p-value significant at <0.05)

Neer score	Nailing	Plating
Excellent & Good	9(90%)	3 (30%)
Fair & Poor	1(10%)	7 (70%)
Total	10 (100%)	10 (100%)

(p-value= 0.0061) chi-square value 7.5. (p-value significant at <0.05)

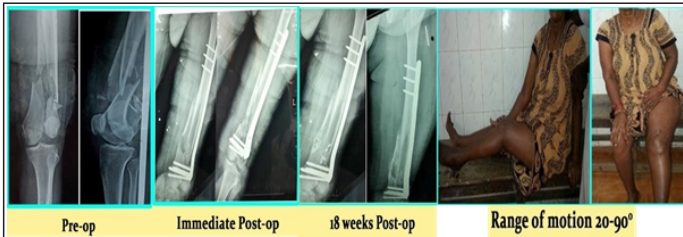

Figure 3

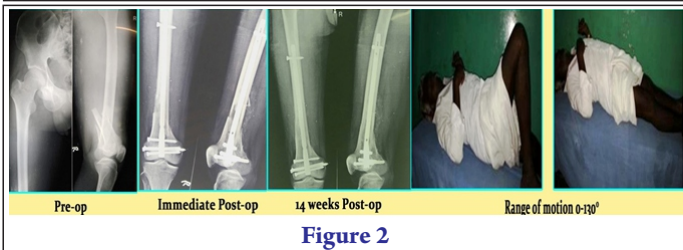


Figure 2

plating (93°).

In this the functional outcome includes pain scoring, walking capacity and degree of possible flexion was better in case of nailing than plating.

The most common intra-operative complication was difficulty in a reduction in closed method with manual traction. This complication was seen in the case of nailing and these cases were dealt with by open reduction. Difficulty in locking was a problem in both nailing (proximal screw) and plating.

The common postoperative complications are knee stiffness and infection which were more in the case of plating. Anterior knee pain was seen in the case of nailing. Other complications are non-union, malunion, delayed union, shortening, angulations etc.

Functional outcome according to Neer's scoring system between two groups, group I (LCP) and group II(DFN) was statistically insignificant for AO Type C2 fractures (p-value = 0.659) while it was significant for type C1 fractures (p-value = 0.002).

In this study, nailing was better in Muller type C1 fracture than plating. Excellent and good results seen in 90% case of nailing than plating which was 30%.

Discussion

Amongst the varied treatment options of distal femoral fractures, two major therapeutic principles can be employed: retrograde IM nailing or locking plate osteosynthesis. Protection of soft-tissue envelope due to the minimally invasive approach and closed reduction

Complications	Nailing	Plating
	No of patients (%)	No of patients (%)
Duration of Surgery (mins)		
60-75	5 (50%)	2 (20%)
75-85	3 (30%)	4 (40%)
85-95	2 (20%)	4 (40%)
Blood Loss (ml)		
<100	7 (70%)	1(10%)
100-200	3 (30%)	5 (50%)
>200	0	4 (40%)
Difficulty in Reduction	3 (30%)	2 (20%)

Complications	Nailing	Plating	Total
Nonunion	Nil	Nil	0
Malunion	1(10%)	Nil	1
Delayed union	1(10%)	1(10%)	2
Infection	Nil	2(20%)	2
Implant failure	Nil	Nil	0
Anterior knee pain	1(10%)	Nil	1
Knee stiffness	Nil	3(30%)	3
Total	3(30%)	6(60%)	9

techniques are better realized using IM nailing.

Luzan TJ et al⁶ concluded in their study that locking plates used to bridge fractures of the distal femur led on average to less callus formation than IM nails and early union. In a systematic review of 29 case series with 415 patients, 5.3% nonunion rates with Locking Plates as opposed to 1.5% in nailing were proclaimed by Herrera DA et al⁷. Gao K. et al⁸ study showed union disturbance rate in the Locking Plate group was higher than in the Retrograde Nailing group. In the present study, the average time taken for union for Plating was around 18 weeks, which was comparable to Henderson et al and Markmiller et al who observed it to be 12 and 14 weeks respectively^{10,11}. The radiological union was defined as bridging callus across three cortices. In cases of nailing average healing time in weeks was 15 weeks which was comparable to Kumar et al 14 weeks and Ingman et al 12 weeks^{12,13}. In the present study, we observed not a single case of non-union both in nailing and plating which is comparable to observation by Kumar et al of 2%. When comparing non-union rates, there is no much difference between nailing and plating series.

Leggon et al¹⁴ found a trend of more knee pain with retrograde distal femoral nailing in patients of distal femur fracture which is consistent with our study.

Functional outcome according to Neer's⁹ scoring system between two groups, group I (LCP) and group II(DFN) was statistically insignificant for AO Type C2 fracture while it was significant for type C1 fractures in our study.

Hoskins et al¹⁵ concluded IMN may be a superior treatment compared with anatomical locking plates for fractures of the distal femur. Distal femur nail has many same advantages as locking plates such as percutaneous placement without disruption of blood supply and direct fracture reduction and being an intramedullary load sharing device allows early load-bearing. But persistent knee pain, development of knee arthrosis remain a setback for nailing.

Conclusion

Retrograde intramedullary supracondylar nail is a good fixation system for distal third femoral fractures intra-articular as well as extra-articular with less operative-time, reduced blood loss and closed reduction without disturbing fracture haematoma and soft tissue. Even with open reduction, soft tissue trauma is less. There are fewer chances of non-union, minimal chances of delayed unions and angular or rotational malunion.

There is no requirement for bone graft. Early surgery, closed reduction and at least two screws in each fragment and early postoperative knee mobilisation are essential for good union and good knee range of motion.

References

- Arneson TJ, Melton LJ 3rd, Lewallen DG, et al. Epidemiology of diaphyseal and distal femoral fractures in Rochester, Minnesota, 1965-1984. *Clin orthop*.1988;234:188-94.
- Schandelmaier P, Partenheimer A, Koenemann B, et al. Distal femoral fractures and LISS stabilization. *Injury* 2001; 32 Suppl 3:SC55-63.
- Gurkan V, Orhun H, Doganay M, Salioglu F, Ercan T, Dursun M, et al. Retrograde intramedullary interlocking nailing in fractures of the distal femur. *Acta Orthop Traumatol Turc*. 2009; 43:199-205.
- Smith WR, Ziran BH, Anglen JO, Stahel PF. Locking plates: tips and tricks. *J Bone Joint Surg Am*. 2007; 89(10):2298-307.
- Markmiller M, Konrad G, Südkamp N: Femur-LISS and distal femoral nail for fixation of distal femoral fractures: are there differences in outcome and complications? *Clin Orthop Relat Res*. 2004; 426:252-257.
- Lujan TJ, Henderson CE, Madley SM, Fitzpatrick DC, Marsh JL, Bottlang M. Locked plating of distal femur fractures leads to inconsistent and asymmetric callus formation. *J Orthop Trauma*. 2010; 24:156-62.
- Herrera DA, Kregor PH, Cole PA, Levy B, Jonsson A, Zlowodzki M. Treatment of acute distal femur fractures above a total knee arthroplasty: Systematic review of 415 cases (1981-2006) *Acta Orthopaedics*. 2008; 79(1):22-27
- Gao K, Gao W, Huang J, Li H, Li F, Tao J, Et Al. Retrograde Nailing Versus Locked Plating Of Extra-Articular Distal Femoral Fractures: Comparison Of 36 Cases. *Med Princ Pract*. 2013; 22:161-66.
- Neer II CS, Grantham SA, Shelton ML. Supracondylar Fracture of the Adult Femur. *The Journal of Bone & Joint Surgery*. 1967; 49A:591-613.
- Henderson CE, Lujan TJ, Kuhl LL, Bottlang M, Fitzpatrick DC, Marsh JL. Healing Complications Are Common After Locked Plating for Distal Femur Fractures. *Clin Orthop Relat Res* 2011 June; 469(6): 1757-1765
- Markmiller M, Konrad G, Südkamp N. Femur-LISS and distal femoral nail for fixation of distal femoral fractures: are there differences in outcome and complications? *Clin Orthop Relat Res*. 2004; (426):252-257
- Kumar A, Jasani VM Butt MS. Management of distal femoral fractures in elderly patients using retrograde titanium supracondylar nails. *Injury*, 31(3): 169-73, Apr 2000
- Ingman AM. Retrograde intramedullary nailing of supracondylar femoral fractures: Design & Development of a New Implant. *Injury*, 33(8); 707-12: Oct 2002
- Leggon RE, Feldmann DD. Retrograde Femoral Nailing: A Focus On The Knee. *Am J Knee Surg*. 2001; 14:109-118.
- Hoskins W, Sheehy R, Edwards ER, Hau RC, Bucknill A, Parsons N, Griffin XL. Nails or plates for fracture of the distal femur? *Bone Joint J*. 2016; 98-B:846-50.

Conflict of Interest: NIL
Source of Support: NIL

How to Cite this Article

Mallik M, Sethi GC, Ray A, Nanda DP | Comparison of the Outcomes of Intra-articular Distal Femur Fracture Managed With Distal Femoral Nail and Locking Compression Plate: A Prospective Study | *Odisha Journal of Orthopaedics & Trauma* | January-June 2021; 42(1): 12-15.