

# Haglund deformity – Resection by lateral approach: A case report and review of literature

Siddhartha Shankar Mohanty<sup>1</sup>, Satya Ranjan Patra<sup>1</sup>, Hemanta Kumar Bamidi<sup>1</sup>,  
Kishore Chandra Das<sup>1</sup>

## Abstract

Haglund's syndrome is a mechanical cause of posterior heel pain leading to functional and sporting disability. It is due to a conflict between the achilles tendon and the postero-superior hypertrophied tuberosity of the calcaneus. Physical examination and standard imaging studies are usually sufficient to establish the diagnosis. The treatment is primarily medical; surgery is indicated after failure of functional treatment and it consists of a resection of the posterior-superior bone prominence of the calcaneus with a good results. In some cases tendo-Achilles repair may be needed. We describe a case of symptomatic Haglund's syndrome that was treated by excision of the mass through lateral approach without tendo-Achilles reconstruction.

**Keywords:** Haglund's syndrome, Calcaneus, Surgical excision, Achilles tendon.

## Introduction

The common causes for the retro calcaneal pain are the insertional tendinitis of Achilles tendon, Haglund's syndrome, and retrocalcaneal bursitis [1, 2]. In 1928, the Swedish orthopedic surgeon, Patrick Haglund described Haglund's syndrome as a painful osseous prominence of the posterosuperior corner of the calcaneus with large posterior palpable callus, and retrocalcaneal bursitis which was caused by rigid heel counters [3]. It is also known as retrocalcaneal exostosis, Mulholland deformity, and 'pump bump.' Although a very common clinical condition, it is still poorly understood. It has no definitive etiology, but various probable causes like a tight Achilles tendon, a high arch of the foot, and heredity have been proposed [4]. The disorder is caused mechanically from abnormally high pressure between the posterosuperior corner of the calcaneus and the Achilles tendon, and the impingement of the retrocalcaneal bursa between the both, leading to the inflammation of the bursa and not by the intrinsic disease of the tendon. Haglund disease is usually observed bilaterally, in women of second or third decade [4]. The diagnosis is made with typical history of pain for the initial few steps of walking after a period of rest, proper clinical examination and interpretation with lateral radiographs of the ankle which reveals a bony prominence at the posterosuperior part of the calcaneal tuberosity, calcaneal bursa swelling and increased density in the pre-Achilles bursa [5]. MRI may be required for ambiguous and clinically doubtful cases [6]. McGarvey et al reported 89% of their patients improved with non-operative treatment and surgery was

indicated for patients not responding to non-operative treatment [7,8] Surgical intervention is the treatment of choice for patients in whom conservative treatment has failed for over 6 months.


## Case report

A 42 year old female complained of pain over the back of both the heels for last 10 years with aggravation of symptoms since last four months with appearance of painful swellings of the heel. The swellings caused difficulty in walking and wearing shoes. Patient was having off and on pain over the years. Pain was associated with activity and occasionally also at rest. There was only temporary relief with oral medications.

On clinical examination the patient was walking with difficulty and support due to pain in both heels. On palpation, hard swellings over the postero-superior aspect of the calcaneus opposed to the insertion of the Achilles tendon (fig. 1A, 1B) were palpated those were tender and right side was more symptomatic. Passive as well as active dorsiflexion of the foot aggravated the pain. The Thomson sign was negative and painful during eliciting. The curvature of the plantar arch was preserved. There was mild local rise of temperature over the right heel with erythema.

The lateral radiograph of the right foot (fig. 1C) showed a salient prominence of the postero-superior angle of the calcaneus with a Fowler-Phillip greater than 70° and a Chauveaux and Liet angle greater than 10°. The diagnosis of bilateral Haglund deformity was done and patient was given oral medications and conservative management for three weeks. But the medical management was unresponsive, therefore surgical treatment was planned.

Under spinal anesthesia, the lesion was approached through a Para-Achilles postero-lateral approach (fig. 2A) of the right ankle while doing gentle dissection of soft-tissues. The interval between the anterior surface of Achilles tendon (fig. 2C) and calcaneum was exposed, taking care not to injure the sural nerve. Bony prominence



<sup>1</sup>Department of Orthopaedics, Hi-Tech Medical College, Bhubaneswar, Odisha India.

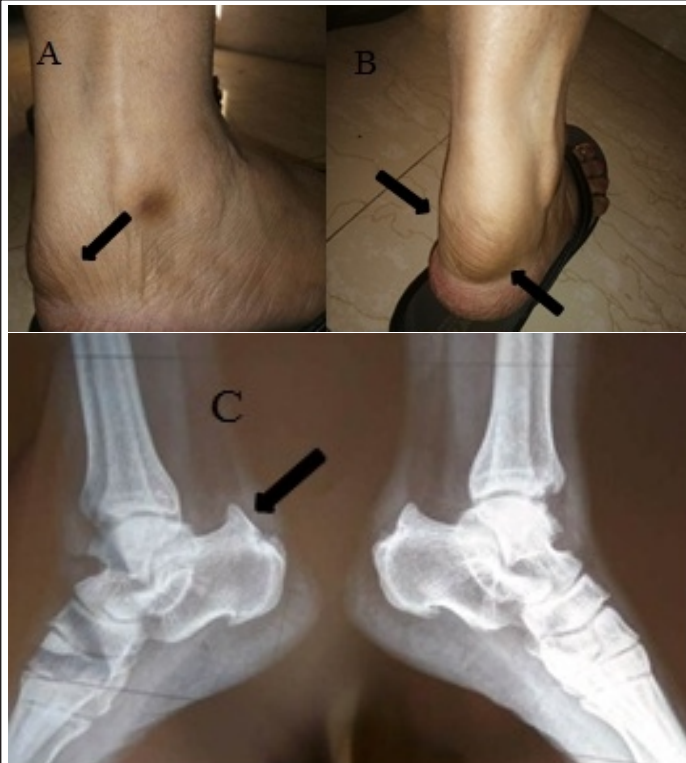### Address of Correspondence

Dr. SatyaRanjan Patra,  
Hi-Tech Medical College, Bhubaneswar, Odisha  
India.

E-mail: drsatyarp@gmail.com

© 2020 by Authors | Available on [www.ojonline.com](http://www.ojonline.com) | DOI: 10.13107/ojot.2020.v41i01.010

This is an Open Access article distributed under the terms of the Creative Commons Attribution Non-Commercial License (<http://creativecommons.org/licenses/by-nc/3.0>) which permits unrestricted non-commercial use, distribution, and reproduction in any medium, provided the original work is properly cited.



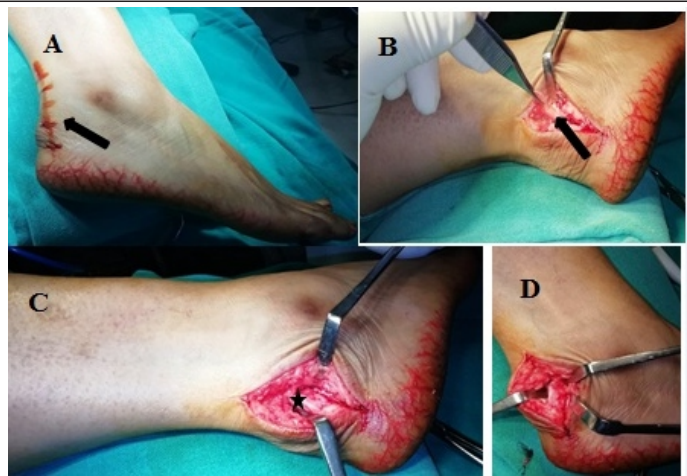
**Figure 1:** [A, B] Bump like swelling on lateral aspect of heel (Black arrows). [C] Lateral radiograph of bilateral feet showing the Haglund deformity

over the postero-superior angle of the calcaneum was identified (fig. 2D). It was large and impinging into the substance of the tendon with presence of bursitis. The bone outgrowth was osteotomized (fig. 3A, 3C) taking care not to damage the tendo-Achilles attachment. Care was taken to excise the overlying periosteum by sharp dissection in total from the excised tuberosity to avoid new bone formation later on. The remnant sharp edges of the tuberosity were smoothed with a rasp and rongeur. The bursal tissue was also excised along with the bony tissue (fig. 3B), followed by thorough washing and closure in layers.

Postoperative radiograph on which postero-superior angle of the calcaneus which is no longer salient after resection of the bone outgrowth. Following surgery the patient was placed in a below knee posterior slab with the ankle placed in 15 degrees of plantar flexion. At 3 weeks following surgery the slab was replaced with cast, ankle in neutral position. Patients were prohibited from weight bearing for the first 7 weeks following surgery. Subsequently patients were allowed to bear weight as tolerated. 8 weeks following surgery patient was allowed to ambulate as tolerated without aids. Physiotherapy in the form of gastro-soleus strengthening exercises was started. The patient was followed for at least 12 months following surgery. At six months of follow-up, functional outcome was satisfactory we note a movable and painless ankle, a clean scar, a good tolerance to the shoes. There was no evidence of pain while walking.

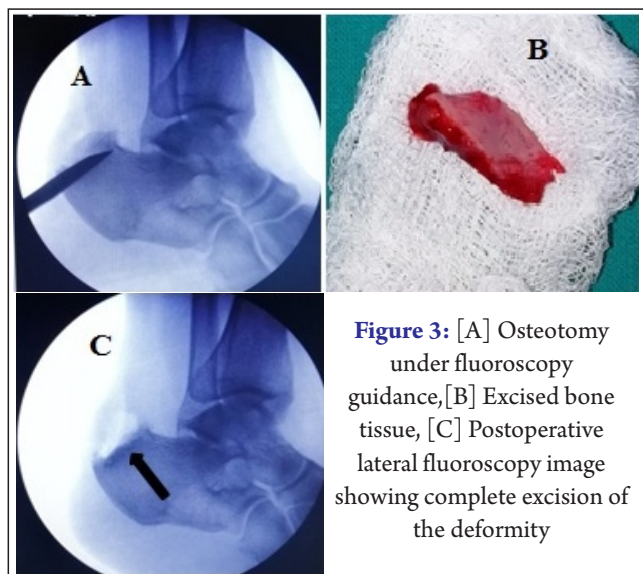
**Discussion**

Many patients with Haglund deformity do not respond to conservative management. In such cases operative treatment is an alternative. However the various surgical methods have been seen to



**Figure 2:** [A] Para-Achilles postero-lateral approach on right foot, [B] The inflamed bursa, [C] Tendo-achilles is carefully dissected away from the bone outgrowth, [D] Posterosuperior bony prominence over the calcaneum

produce mixed results, making it difficult to set definite guidelines as to when operative treatment is needed [11, 12]. The use of various radiological parameters for Haglund deformity does not carry any clinical significance in terms of planning surgical intervention. Lu et al in their analysis and relation of Fowler angle and parallel pitch lines in Haglund deformity concluded the difference of these parameters between the Haglund heels and normal heels was not statistically significant [13]. Fowler angle of 44 degree to 69 degree is considered normal and angle more than 75 degree is associated with prominent postero-superior prominence of the calcaneum a feature suggestive of Haglund deformity. The fact that calcaneal osteotomy produces outcomes that justify its use in patient with resistant cases. The pre-operative AOFAS score was 54/100 and post-operative AOFAS score at the final follow up at 1 year follow up was 86/100. The results are similar to those reported by Samarcoet et al and Sella et al [14, 15]. The key to successful outcome is the adequate resection of the bone. Sella et al highlighted the importance of enough bone being resected to allow decompression of the tendon and retrocalcaneal bursa. If adequate bone is not excised there will be persistent irritation of the



**Figure 3:** [A] Osteotomy under fluoroscopy guidance, [B] Excised bone tissue, [C] Postoperative lateral fluoroscopy image showing complete excision of the deformity

soft tissue with subsequent recurrence and failure of surgical intervention [15]. Adequate resection of the periosteum on the medial side is difficult through the lateral approach. To successfully perform resection of periosteum on the medial side, Anderson et al suggested that tendon splitting approach allows for better surgical results [16]. But tendon splitting may result in delayed healing and excessive scar formation with adherence of overlying skin to tendon leading to shoe wear problems. Few studies recommend routine repair and reinforcement of the TA following Haglund excision [17]. But in our case no repair was required.

## Conclusion

The lateral approach to calcaneum for excision of the Haglund deformity with surgical debridement of the bursa is an effective method for these lesions and TA repair may not be necessary in every case. From the literature review, the radiological parameters do not appear to have much significance and treatment plan should be decided on clinical grounds. The chief limitation of the surgical procedure is prolonged recovery time. The prolonged recovery and possible soft tissue complications should be explained to the patients before moving ahead with surgical interventions.

## References

1. Clancy WG. Runners' injuries. Part two. evaluation and treatment of specific injuries. *Am J Sports Med* 1980;8:287-9.
2. Fiamengo SA, Warren RF, Marshall JL, Vigorita VT, Hersh A. Posterior heel pain associated with a calcaneal step and Achilles tendon calcification. *Clin Orthop Relat Res* 1982;162:203-11.
3. Haglund P. Beitrag zur Klinik der Achilles tendon. *Zeitschr Orthop Chir* 1928;49:49-58.
4. Jerosch J, Schunck J, Sokkar SH. Endoscopic calcaneoplasty (ECP) as a surgical treatment of haglund's syndrome. *Knee Surg Sports Traumatol Arthrosc* 2007;15:927-34.
5. Van Dijk CN, van Dyk CE, Scholten PE, Kort NP. Endoscopic calcaneoplasty. *Foot Ankle Clin* 2006;2:439-46.
6. Pavlov H, Heneghan MA, Hersh A, Goldman AB, Vigorita V. The Haglund syndrome: initial and differential diagnosis. *Radiology* 1982;144(1):83-8.
7. Haglund P. Beitrag zur Klinik der Achillessehne. *Z Orthop Chir* 1927; 49: 49-58.
8. McGarvey WC, Palumbo RC, Baxter DE, Leibman BD. Insertional Achilles tendinosis: surgical treatment through a central tendon splitting approach. *Foot Ankle Int*. 2002; 23: 19-25.
9. McGarvey WC, Palumbo RC, Baxter DE, Leibman BD. Insertional Achilles tendinosis: surgical treatment through a central tendon splitting approach. *Foot Ankle Int*. 2002; 23: 19-25.
10. Dr O. Laffenetre, Dr J. Lucas, Pr D. Chauveaux Document d'information du patient sur le syndrome de HAGLUND CHU - Hopitaux de Bordeaux. 2011.
11. Angermann P. Chronic retrocalcaneal bursitis treated by resection of the calcaneus. *Foot Ankle*. 1990;10(5):285-7.
12. Green AH, Hass MI, Tubrity SP, Goldberg MM, Perry JB. Calcaneal osteotomy for retrocalcaneal exostosis. *Clin Podiatr Med Surg*. 1991;8:659-65.
13. Lu CC, Cheng YM, Fu YC, Tien YC, Chen SK. Angle analysis of Haglund syndrome and its relationship with osseous variations and Achilles tendon calcification. *Foot Ankle Int*. 2007;28(2):181-5.
14. Sammarco GJ, Taylor AL. Operative management of Haglund deformity in the non athlete: a retrospective study. *Foot Ankle Int*. 1998;19:724-9.
15. Sella EJ, Caminear DS, McLarney EA. Haglund syndrome. *J Foot Ankle Surg*. 1998;37:110-4.
16. Anderson JA, Suero E, O'Loughlin PF, Kennedy JG. Surgery for Retrocalcaneal Bursitis: A Tendon-splitting versus a Lateral Approach. *Clin Orthop Relat Res*. 2008;466(7):1678-82.
17. V. Gulati, M. Jaggard, S. S. Al-Nammari et al., "Management of achilles tendon injury: a current concepts systematic review," *World Journal of Orthopaedics*, vol. 6, no. 4, pp. 380-386, 2015.

Conflict of Interest: NIL  
Source of Support: NIL

### How to Cite this Article

Mohanty S S, Patra S R, Bamidi H K, Das K C. | Haglund deformity – resection by lateral approach: a case report and review of literature. | *Odisha Journal of Orthopaedics & Trauma* | Jan-June 2020; 41(1): 31-33.